

The Clinical Consequences of Flexion Gap Asymmetry in Total Knee Arthroplasty

Jose Romero, MD, Thomas Stähelin, MD, Christoph Binkert, MD, Christian Pfirrmann, MD, Jurg Hodler, MD, and Oliver Kessler, MD, MS

Abstract: This study was carried out to compare femoral component rotation of 18 knees from 18 patients who suffered from lateral flexion instability after total knee arthroplasty (Western Ontario and McMaster University Osteoarthritis [WOMAC], 6.4 points; International Knee Society [IKS] score, 119 points) with 10 asymptomatic controls (WOMAC, 0.1 points; IKS score, 182 points) after total knee arthroplasty. The symptomatic patients showed increased lateral joint laxity as determined by fluoroscopic stress radiography. Femoral component rotation was determined by computed tomography scans. The femoral component rotation was more internally rotated in symptomatic patients (5.5°) than in controls (1.0°) ($P = .04$). Varus laxity in flexion was higher in symptomatic patients (11.0°) than in controls (7.0°) ($P < .001$). Increased lateral flexion laxity is associated with increased internal femoral component rotation and a less favorable clinical outcome. **Key words:** total knee arthroplasty, femoral component malrotation, flexion gap asymmetry, flexion instability, fluoroscopic stress radiography.

© 2007 Elsevier Inc. All rights reserved.

Total knee arthroplasty is a reliable procedure to relieve pain and restore function with a predictable long-term outcome [1-11]. However, unexplained knee pain in patients with radiological normal total knee arthroplasty is a well-known phenomenon [12]. Flexion instability has recently been recognized as one possible source for postoperative discomfort such as pain on the medial tibial metaphysis, soft tissue tenderness involving the tendons of the pes anserine, a sense

of instability, and recurrent knee joint effusion [13]. Increased anteroposterior flexion laxity has been attributed to widening of the flexion gap [14] due to early, progressive incompetence of the posterior cruciate ligament in posterior cruciate retaining total knee arthroplasty [15]. Increased varus flexion laxity may occur as a consequence of flexion gap asymmetry due to internal malrotation of the femoral component [16]. The condition is rarely recognized during clinical examination of a patient with painful total knee arthroplasty because varus-valgus stability assessment in flexion is not routinely performed. Stress fluoroscopy has recently been presented to be a valid method to quantify flexion laxity after total knee arthroplasty [17].

The purpose of this study was to compare femoral component rotation and laxity in flexion of patients with lateral flexion instability with patients after successful total knee arthroplasty.

From the Department of Orthopedic Surgery, University of Zurich, Balgrist, Switzerland.

Submitted November 26, 2004; accepted April 12, 2006.

No benefits or funds were received in support of the study.

Reprint requests: Jose Romero, MD, Endoclinic Zurich, Klinik Hirslanden, Witellikerstr. 40, 80032 Zurich, Switzerland.

© 2007 Elsevier Inc. All rights reserved.

0883-5403/07/1906-0004\$32.00/0

doi:10.1016/j.arth.2006.04.024

Material and Methods

Recruitment of Patients and Controls

Eighteen consecutive patients (median age, 71.5 years; range 53-80 years; 16 women, 2 men) with a persistent painful knee and clinically identified increased lateral flexion laxity after posterior cruciate retaining fixed-bearing total knee arthroplasty with patellar resurfacing (median postoperative follow-up of 42 months; range, 24-156 months) were included in the study. Exclusion criteria were implant loosening or infection, scar neuroma, patellar maltracking, oversized components, flexion contracture greater than 5° , reduced flexion less than 110° , and instability in extension. All knees had been replaced for primary degenerative joint disease. The median global Western Ontario and McMaster University Osteoarthritis (WOMAC) score of the symptomatic patients was 6.4 points (25% value, 5.8 points; 75% value, 7.1 points). The median function score (International Knee Society [IKS]) of the symptomatic patients was 65 points (25% value, 53 points; 75% value, 95 points). Ten patients

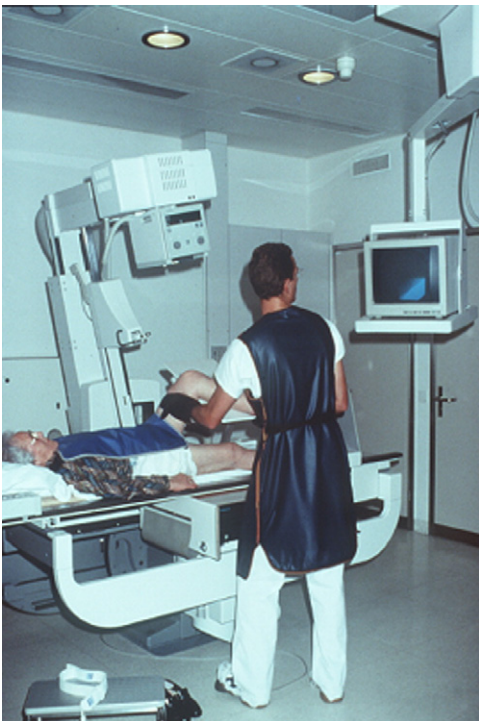

Fig. 1. Setup of the fluoroscopic stress radiography in our radiological department. The radiographic examination was performed with the patient lying on a radiolucent board consisting of 3 parts connected by hinges, with the hip and knee joints flexed.

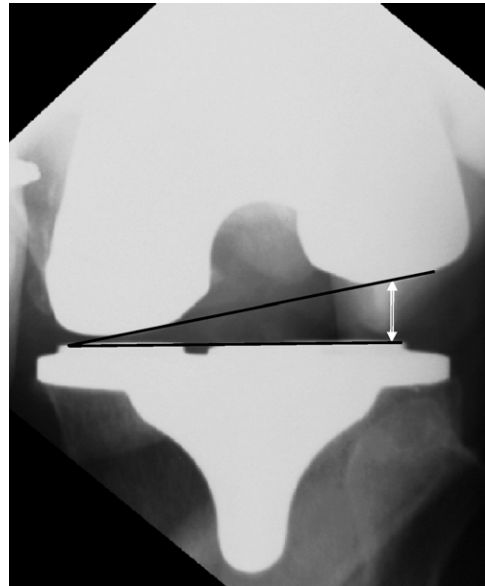


Fig. 2. Increased lateral flexion laxity as determined by fluoroscopic stress radiography. Medial and lateral joint opening in flexion and extension is determined by the angle between the tibial tray and the line connecting the most distal points of the distal and posterior condyles of the femoral component. The angle between the PCA and the surface of the tibial tray measures 12° .

(7 women, 3 men) with asymptomatic total knee arthroplasty who had been operated for the same conditions were matched for age (median age, 70.3 years; range, 55-82 years), and were followed up for 44 months (range, 26-151 months), and served as a control group. They had a WOMAC score of 0.1 points (25% value, 0.1 points; 75% value, 0.3 points). The median function score (IKS) of the asymptomatic patients was 92 points (25% value, 90 points; 75% value, 97 points).

Clinical Outcome

The clinical outcome was assessed using the WOMAC Index [18]. The scoring was assessed on an ordinal scale from 0 to 10. The best possible outcome is represented with 0 point, the worst with 10 points. The IKS knee and function score was applied in addition [19]. A maximum of 200 points represents the best possible outcome.

Inclusion criteria for the controls were an uneventful postoperative course, normal postoperative x-rays, a global WOMAC of less than 1, and a total IKS of greater than 160 at the time of evaluation.

Imaging

Plain X-rays. Plain x-rays (anteroposterior, lateral, and Merchant view [20]) were used to ex-




Fig. 3. Transverse computed tomography scan of an internally malrotated femoral component (same patient as in Fig. 2). Internal rotation of the femoral component is determined by the angle between the transepicondylar axis (TEA) and the tangential line of the posterior condyles (PCAs) of the femoral component. For the measurement, the line of the TEA is moved parallel (lowest line). The angle between the TEA and the PCA measures 10° (right side of the computed tomography picture corresponds to lateral, left to medial).

clude patients with radiological signs of loosening, implant oversizing, malpositioning, and patellar maltracking. The hip-knee-ankle angle was measured on long leg x-rays.

Fluoroscopic Stress Radiography. The reliability of fluoroscopic stress radiography for the flexed knee has been described earlier [17] (Fig. 1). It is performed with the patient lying supine on a radiolucent bench with the hip and knee flexed to 90° each. The bench consists of 3 boards connected with hinges. The length of the board to which the thigh is leaned against can be adjusted manually to

accommodate the patient's leg length. The hinges allow the hip to be abducted and adducted and the knee to be flexed. Fluoroscopy is set at a distance of 150 cm. The beam is inclined by 5° in a craniocaudal direction to avoid overlay with the femoral shaft and the soft tissues of the thigh. A handheld spring scale is used to apply a perpendicular force of 15 N to the tibia either in a varus or valgus direction. The spring was attached 30 cm distal to the tibiofemoral joint line resulting in a moment of 4.5 Nm. Using the image intensifier, the femoral component is projected orthogonally, and an x-ray at 60 kV is taken. Fluoroscopic stress radiography in extension is performed without the bench with the knee fully extended. The x-ray beam is directed perpendicular to the examination table. The same handheld spring is used in the same manner to open the lateral and medial joint space.

Medial and lateral joint opening in flexion and extension is determined by the angle between the tibial tray and the line connecting the most distal points of the distal and posterior condyles of the femoral component (Fig. 2).

Computed Tomography. To determine rotation of the femoral component of the knee prosthesis, a computed tomography scan (CT, Somtom Plus 4 Siemens, Erlangen, Germany; single detector, spiral scans, 6-mm table speed) of the distal femur was obtained using a 5-mm collimation 140 kV, 512×512 matrix, rotation time 1 second, and 185 mA. The rotation of the femoral component was assessed by measuring the angle between the line connecting the most prominent condylar peaks (anatomic transepicondylar axis [TEA]) and the tangential line on the posterior condyles of the femoral component (posterior condylar axis [PCA]) [21] (Fig. 3).

Data Analysis and Statistics

Using the Mann-Whitney rank sum test, comparisons between the symptomatic patients and

Table 1. Femorotibial Laxity (in Full Knee Extension and 90° of Flexion), Coronal and Axial Alignment as Determined by Fluoroscopic Stress Radiography, Long-Standing X-Rays, and Computed Tomography Scans for Symptomatic Patients ($n = 18$) and Controls ($n = 10$) (Median and 25%/75% values)

		Symptomatic ($n = 18$)	Controls ($n = 10$)	P
Extension	Varus laxity	4.0° ($3.0^\circ/4.0^\circ$)	4.0° ($3.8^\circ/4.3^\circ$)	.44
	Valgus laxity	2.0° ($1.3^\circ/3.8^\circ$)	2.0° ($2.0^\circ/4.3^\circ$)	.46
Flexion	Varus laxity	11.0 ($9.5^\circ/12^\circ$)	7.0° ($6.4^\circ/8.0^\circ$)	<.001
	Valgus laxity	4.0° ($3.0^\circ/4.0^\circ$)	5.0° ($4.3^\circ/6.5^\circ$)	.36
Femoral component rotation*		$+5.5^\circ$ ($+4^\circ; +8^\circ$)	$+1.0^\circ$ ($0^\circ; +6^\circ$)	.04
Hip-knee-ankle axis†		0.0° ($-1.0; +2.0$)	0.0° ($-2.0; +0.6$)	.64

*Internal rotation, +.

†Varus, +; valgus, -.

controls were made for laxity measurements in flexion and extension, for alignment in the coronal plane, and for femoral component rotation. The values are given in median values, and the lower and higher numbers represent first (25% value) and third quartiles (75% value).

Results

The results of the fluoroscopic stress radiography are summarized in [Table 1](#). Lateral joint opening in flexion was on average 4° larger in symptomatic patients than in controls, and this finding was statistically significant. Medial joint opening in flexion was not increased in either group. Medial and lateral joint opening in extension was not increased neither in the symptomatic nor in the control group. Joint opening in extension was on average 2° higher on the lateral side compared with the medial side.

The femoral component referenced on the anatomic TEA was statistically significantly more internally rotated in symptomatic patients than in controls ([Table 1](#)). The difference of the median internal femoral component rotation between the symptomatic patients and controls was 4.5°. Externally rotated femoral components referenced on the anatomic TEA were not found neither in symptomatic nor in asymptomatic patients.

For symptomatic patients, the median aggregate score for physical function dimension was 7.1 points. The aggregate scores for pain and stiffness dimensions were 5.9 points and 5.5, respectively. Median scores for pain on stair climbing (9.0 points), reduced function on descending stairs (9.0 points), rising from a chair (9.5 points), getting in and out of a car (8.5 points), getting in and out of bath (8.5 points) were lowest.

Discussion

Symmetrically balanced collateral soft tissues in extension and in flexion [22,23] and alignment of the tibial and femoral components perpendicular to the mechanical axis in the coronal plane [24] are major surgical goals in total knee arthroplasty. Erroneous resection of the tibial plateau and distal femoral condyles or inadequate soft tissue release for varus or valgus contracture will result in an asymmetric extension gap. Extension gap imbalance because of insufficient soft tissue release may cause polyethylene edge overload [25] and consequently accentuate wear [26]. Overrelease of the collateral structures may result in symptomatic

instability [27]. Mild to moderate increased varus-valgus laxity in extension has been reported to be of no clinical importance [28]. However, instability may be an important cause for total knee arthroplasty failure [29] and accounted for 21% of 212 revision total knee arthroplasties in the series by Sharkey et al [30]. Fehring et al [31] reported on 27% instability cases in their total knee revision population of 440 patients who had to be revised after a follow-up of less than 5 years after primary total knee arthroplasty.

Increased varus or valgus laxity in flexion because of femoral component malrotation has extensively been examined in cadaveric studies under loaded [16] and unloaded conditions [32]. Although femoral component malrotation is considered the major cause for flexion gap imbalance [32,33], little is known on the clinical consequences. Laskin [34] reported on patients with medial tibial pain if the femoral component was not externally rotated to allow rectangularization of the flexion gap. However, it is not known how much flexion gap asymmetry may be tolerated clinically because no studies have been carried out to measure flexion laxity in vivo after total knee arthroplasty.

Varus and valgus laxity in flexion might be difficult to quantify by clinical examination. In a cadaver study, Grood et al [35] compared manually assessed medial and lateral joint opening with varus and valgus laxity determined by means of an Instron testing system. They proved that erroneous laxity assessment in flexion is likely to occur by clinical examination even when the primary restraint is missing and the testing system demonstrates a large joint opening. The application of fluoroscopic stress radiography on a patient lying relaxed on a designated radiolucent bench proved to be a feasible, inexpensive, fast, safe, and reproducible method for detecting increased varus-valgus laxity of the knee in flexion on a routine base [17]. The moment applied to the tibia has to be pain-free, avoiding quadriceps and hamstrings cocontraction, which increases tibiofemoral joint reaction force and decreases joint opening [36].

In the present study, fluoroscopic stress radiography in flexion revealed increased lateral joint opening in symptomatic patients as compared with asymptomatic patients, and increased lateral joint opening was associated with increased internal rotation of the femoral component. A recent study using a 3-dimensional interactive model-fitting technique for 2-dimensional fluoroscopic dynamic images confirms that increased femorotibial separation ("condylar lift-off") under weight-bearing conditions in flexion was more pronounced on the

lateral side and was associated with femoral component malrotation [37]. A study by Stiehl et al [38] confirms that condylar lift-off occurs in clinically successful total knee arthroplasties, but it is not known to what extent this condition may be clinically tolerated. An exaggerated condylar-lift off due to increased lateral flexion laxity because of a malrotated femoral component may disturb knee kinematics and ultimately accentuate edge loading, which has been implicated as a cause of premature polyethylene failure [39]. The WOMAC test revealed that there are specific symptoms associated with increased flexion gap imbalance due to internal femoral component malrotation. The predominant patient complaints were pain on stair climbing, reduced function on descending stairs, rising from a chair, getting in and out of a car, and getting in and out of bath. Attfield et al [40] reported also on knees that were not balanced in flexion but were fully balanced in extension. Proprioception was reduced in such knees compared with knees that were properly balanced in flexion and extension.

In summary, increased flexion gap imbalance yields poorer clinical results and is associated with increased internal femoral component malrotation. The unbalanced soft tissues may create higher strains in the surrounding tissues and consequently produce pain. Avoidance of an asymmetric flexion gap should be a surgical goal.

References

1. Aglietti P, Buzzi R, DeFelice R, et al. The Insall-Burstein total knee replacement in osteoarthritis. *J Arthroplasty* 1999;14:560.
2. Callahan CM, Drake BG, Heck DA, et al. Patient outcomes following tricompartmental total knee replacement. *JAMA* 1994;271:1349.
3. Colizza WA, Insall JN, Scuderi GR. The posterior stabilized total knee arthroplasty. *J Bone Joint Surg* 1995;77-A:1713.
4. Ewald FC, Wright RJ, Poss R, et al. Kinematic total knee arthroplasty. *J Arthroplasty* 1999;14:473.
5. Falatyn S, Lachiewicz PF, Wilson FC. Survivorship analysis of cemented total condylar knee arthroplasty. *Clin Orthop* 1995;317:178.
6. Font-Rodriguez DE, Scuderi GR, Insall JN. Survivorship of cemented total knee arthroplasty. *Clin Orthop* 1997;317:79.
7. Keating EM, Meding JB, Faris PM, et al. Long-term follow-up of nonmodular total knee replacements. *Clin Orthop* 2002;1:34.
8. Ranawat CS, Flynn Jr WF, Saddler S, et al. Long-term results of total knee condylar knee arthroplasty. *Clin Orthop* 1993;286:94.
9. Ritter MA, Herbst SA, Keating EM, et al. Long-term survival analysis of a posterior cruciate-retaining total condylar knee arthroplasty. *Clin Orthop* 1994;309:136.
10. Schai PA, Thornhill TS, Scott RD. Total knee arthroplasty with the PFC system. *J Bone Joint Surg* 1998;80-B:850.
11. Scuderi GR, Insall JN, Windsor RE, et al. Survivorship of cemented knee replacement. *J Bone Joint Surg* 1989;71-B:798.
12. Mont MA, Serna FK, Krackow KA, et al. Exploration of radiographically normal total knee replacements for unexplained pain. *Clin Orthop Relat Res* 1996;331:216.
13. Pagnano MW, Hanssen AD, Lewallen DG, et al. Flexion instability after primary posterior cruciate retaining total knee arthroplasty. *Clin Orthop* 1998;356:39.
14. Mihalko WM, Krackow KA. Posterior cruciate ligament effects on the flexion space in total knee arthroplasty. *Clin Orthop Relat Res* 1999;360:243.
15. Waslewski GL, Marson BM, Benjamin JB. Early, incapacitating instability of posterior cruciate ligament-retaining total knee arthroplasty. *J Arthroplasty* 1998;13:763.
16. Romero J, Duronio JF, Sohrabi A, et al. Varus and valgus flexion laxity of total knee alignment methods in loaded cadaveric knees. *Clin Orthop* 2002;394:243.
17. Stähelin T, Kessler O, Pfirrmann C, et al. Fluoroscopically assisted stress radiography for varus-valgus assessment in flexion after total knee arthroplasty. *J Arthroplasty* 2003;18:513.
18. Bellamy N, Buchanan WW, Goldsmith CH, et al. Validation-study of WOMAC—a health-status instrument for measuring clinically important patient relevant outcomes to antirheumatic drug-therapy in patients with osteo-arthritis of the hip or knee. *J Rheumatol* 1988;15:1833.
19. Insall JN, Dorr LD, Scott RD, et al. Rationale of the Knee-Society clinical rating system. *Clin Orthop* 1989;248:13.
20. Merchant AC, Mercer RL, Jacobson RH, et al. Roentgenographic analysis of patellofemoral congruence. *J Bone Joint Surg* 1974;56-A:1391.
21. Yoshino N, Takai S, Ohtsuki Y, et al. Computed tomography measurement of the surgical and clinical transepicondylar axis of the distal femur in osteoarthritic knees. *J Arthroplasty* 2001;16:493.
22. Freeman MAR. Anonymus arthritis of the knee: clinical features and surgical management. New York: Springer-Verlag; 1980.
23. Insall JN. Choices and compromises in total knee arthroplasty. *Clin Orthop* 1988;226:43.
24. Insall JN. Surgical techniques and instrumentation in total knee arthroplasty. In: Insall JN, Windsor RE, Kelly MA, et al, editors. *Surgery of the knee*. New York: Churchill Livingstone; 1993. p. 739.
25. Hsu RWW, Himeno S, Coventry MB, et al. Normal axial alignment of the lower extremity and load-

- bearing distribution at the knee. *Clin Orthop* 1990;255:215.
26. Wasielewski RC, Galante JO, Leighty RM, et al. Wear patterns on retrieved polyethylene tibial inserts and their relationship to technical considerations during total knee arthroplasty. *Clin Orthop Relat Res* 1994;31.
 27. Griffin WL. Prosthetic knee instability: prevention and treatment. *Curr Opin Orthop* 2001;12:37.
 28. Edwards E, Miller J, Chan KH. The effect of postoperative collateral ligament laxity in total knee arthroplasty. *Clin Orthop* 1988;236:44.
 29. Mitts K, Muldon MP, Gladden M, et al. Instability after total knee arthroplasty with the Miller Gallante II total knee—5-7 years follow-up. *J Arthroplasty* 2001;16:422.
 30. Sharkey PF, Hozack WJ, Rothman RH, et al. Why are total knee arthroplasty failing today. *Clin Orthop* 2002;404:7.
 31. Fehring TK, Odum S, Griffin WL, et al. Early failures in total knee arthroplasty. *Clin Orthop* 2001;392:315.
 32. Anouchi YS, Whiteside LA, Kaiser AD, et al. The effects of axial rotational alignment of the femoral component on knee stability and patellar tracking in total knee arthroplasty demonstrated on autopsy specimens. *Clin Orthop* 1993;287:170.
 33. Fehring TK. Rotational malalignment of the femoral component in total knee arthroplasty. *Clin Orthop* 2000;380:72.
 34. Laskin RS. Flexion space configuration in total knee arthroplasty. *J Arthroplasty* 1995;10:657.
 35. Grood ES, Stowers SF, Noyes FR. Limits of movement in the human knee. *J Bone Joint Surg* 1988;70-A:88.
 36. Mac Williams BA, Wilson DR, Des Jardins JD, et al. Hamstrings cocontraction reduces internal rotation, anterior translation, and anterior cruciate ligament load in weight-bearing flexion. *J Orthop Res* 1999;17:817.
 37. Insall JN, Scuderi GR, Komistek RD, et al. Correlation between condylar lift-off and femoral component alignment. *Clin Orthop* 2002;403:143.
 38. Stiehl JB, Dennis DA, Komistek RD, et al. In vivo determination of condylar lift-off and screw-home in a mobile-bearing total knee arthroplasty. *J Arthroplasty* 1999;14:293.
 39. Lewis P, Rorabeck CH, Bourne RB, et al. Posteromedial tibial polyethylene failure in total knee replacements. *Clin Orthop* 1994;299:11.
 40. Attfield SF, Wilton TJ, Pratt DJ, et al. Soft-tissue balance and recovery of proprioception after total knee replacement. *J Bone Joint Surg Br* 1996;78:540.